

# TransPRK: No-touch technique with SCHWIND AMARIS

## The new dimension in surface treatments

The SCHWIND AMARIS laser systems provide a sophisticated approach to carry out no-touch, all-laser surface ablations in a single step.

### Precise ablation with the laser

With the TransPRK (transepithelial PRK), the epithelium is ablated by SCHWIND AMARIS laser systems. This approach avoids the eye coming in contact with any instrument.


TransPRK is also an advanced surface laser treatment because the epithelium is removed more precisely, uniformly and easily than with either manual or alcohol-assisted debridement.

### Exactly calculated epithelial thickness profile


TransPRK treats refractive errors by superimposing an aspheric ablation profile with a defined epithelial thickness profile based on literature values and mean epithelial profiles of large based populations. TransPRK applies an epithelial thickness profile that is thinner with  $55\ \mu\text{m}$  at the centre than with  $65\ \mu\text{m}$  at the periphery.

### Compensating different tissue ablation


Changes in corneal curvature accompanied by a non-normal incidence of the laser beam cause efficiency and reflection losses. The SCHWIND CAM compensates for these losses, thereby avoiding hyperopic shift. In addition, the sophisticated software compensates for the slight differences in photoablative rates of the stroma and the epithelial tissue.




Regular cornea before TransPRK




Ablation of the refractive component



Ablation of the epithelial component



Stromal bed after TransPRK



Regenerated cornea after TransPRK

### TransPRK in regular corneas

Compared to LASEK and PRK, treatment with TransPRK speeds up the healing process in regular corneas. Visual outcomes are achieved significantly earlier – even in high myopic eyes (more than 8 D).

In contrast to LASIK or Femto-LASIK, TransPRK does not require suction of the eye. As a result of a typically higher residual stromal thickness, this method offers higher safety for the patient: no corneal flap has to be prepared and thus there is no additional weakening of the cornea.


### TransPRK in irregular corneas

TransPRK in combination with corneal wavefront allows maximum correspondence between the corneal topography and the ablation profile. It is preferable for patients who need retreatment after radial keratotomy or corneal transplantation. The TransPRK technique is also useful in all cases where a difficult epithelial flap is expected or when the epithelium covers corneal irregularities of the stromal tissue.


Moreover it can be used to treat haze, scarred corneal tissue and keratoconus before corneal collagen cross-linking.

Because TransPRK applies the laser beam directly over the epithelium, it acts as a smoothing agent for the residual stromal bed.

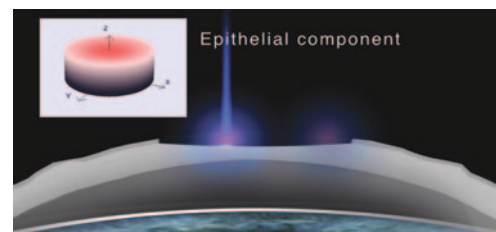
- Shortens treatment time
- Minimises risk of corneal dehydration
- Speeds up the healing process



Irregular cornea before TransPRK



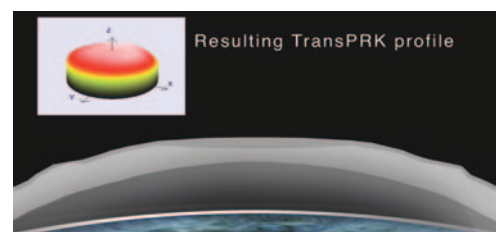
Ablation of the refractive component



Ablation of the epithelial component



Stromal bed after TransPRK



Regenerated cornea after TransPRK